



ACCESO  ABIERTO

# Acute myelitis as a manifestation of SARS-CoV-2 infection

*Mielitis aguda como manifestación de infección por SARS-COV-2*

Natalia Hernández-Beltrán<sup>1</sup> , Mónica Flórez<sup>2</sup> , Jorge Rico-Fontalvo<sup>3</sup> , Rodrigo Daza-Arnedo<sup>3</sup> , Víctor Leal-Martínez<sup>4</sup> , Nehomar Pájaro-Galvis<sup>5</sup> , Christian Sánchez-Álvarez<sup>6</sup> , Ariel Bello-Espinosa<sup>7</sup>  & Maria Raad-Sarabia<sup>8</sup> 

<sup>1</sup> Departamento de Neurología, Clínica Central Fundadores, Medellín-Colombia.

<sup>2</sup> Departamento de Radiología, Clínica León XIII, Medellín-Colombia.

<sup>3</sup> Asociación Colombiana de Nefrología, Medellín-Colombia.

<sup>4</sup> Clínica Somer, Medellín-Colombia.

<sup>5</sup> Hospital Bocagrande, Cartagena-Colombia.

<sup>6</sup> Departamento de Medicina, Universidad de Antioquia.

<sup>7</sup> Departamento de Medicina Interna, Universidad de Cartagena, Cartagena-Colombia.

<sup>8</sup> Departamento de Medicina Interna, Universidad del Sinú. Cartagena-Colombia.

## ABSTRACT

**Introduction:** the infection generated by the new SARS-CoV-2 coronavirus has shown a growing increase in recent months, showing varied clinical manifestations, from mild symptoms to severe pulmonary involvement. In addition, atypical clinical forms have been described, in which extrapulmonary symptoms predominate; among them, cases of concurrent neurological manifestations have been reported. Based on the identification of coronavirus in the central nervous system in the 2020 SARS-CoV outbreak, a potential neurotropism of SARS-CoV-2 has been raised. Few patients with acute encephalitis, ischemic cerebrovascular events and spinal cord involvement associated with SARS-CoV-2 have been described in the world literature.

**Clinic case:** 57-year-old man with a history of controlled hypertension, presented to the emergency department with eight days of non-productive cough, associated with a subjective increase in body temperature. Physical examination on admission revealed tachypnea, fever of 38 °C, normal blood pressure and heart rate; a chest x-ray was performed that shows severe pneumonia, and later he progressed to ventilatory failure that required intensive care unit management for support with noninvasive mechanical ventilation. SARS-CoV2 infection confirmed with RT-PCR.

**Conclusions:** in this report we present a patient with transverse myelitis concurrent to Covid-19, we review the literature and discuss the clinical and imaging findings given by the disease.

**Keywords:** Covid-19; Transverse myelitis; Plasmapheresis.

## RESUMEN

**Introducción:** la infección generada por el nuevo coronavirus SARS-CoV-2 ha mostrado un aumento creciente en los últimos meses, presentando manifestaciones clínicas variadas desde síntomas leves hasta afectación pulmonar

**Para citaciones:** Hernández Beltrán, N., Flórez, M., Rico Fontalvo, J., Daza Arnedo, R., Leal Martínez, V., Pájaro Galvis, N., Sánchez Álvarez, C., Bello Espinosa, A., & Raad Sarabia, M. (2022). Acute myelitis as a manifestation of SARS-COV-2 infection. *Revista Ciencias Biomédicas*, 11(4), 286-290.  
<https://doi.org/10.32997/rcb-2022-3734>

Recibido: 22 de marzo de 2022

Aprobado: 14 de julio de 2022

**Autor de correspondencia:**

Jorge Rico-Fontalvo  
[jorgericof@yahoo.com](mailto:jorgericof@yahoo.com)

**Editor:** Inés Benedetti. Universidad de Cartagena-Colombia.

**Copyright:** © 2022. Hernández Beltrán, N., Flórez, M., Rico Fontalvo, J., Daza Arnedo, R., Leal Martínez, V., Pájaro Galvis, N., Sánchez Álvarez, C., Bello Espinosa, A., & Raad Sarabia, M. Este es un reporte de caso de acceso abierto, distribuido bajo los términos de la licencia <https://creativecommons.org/licenses/by-nc-nd/4.0/> la cual permite el uso sin restricciones, distribución y reproducción en cualquier medio, siempre y cuando que el original, el autor y la fuente sean acreditados.



grave. Además, se han descrito formas clínicas atípicas, en las que predominan los síntomas extrapulmonares; entre ellas, se han notificado casos de manifestaciones neurológicas concurrentes. A partir de la identificación de coronavirus en el sistema nervioso central en el brote de SARS-CoV de 2020, se ha planteado un posible neurotropismo del SARS-CoV-2. En la literatura mundial se han descrito pocos pacientes con encefalitis aguda, eventos cerebrovasculares isquémicos y afectación de la médula espinal asociados al SARS-CoV-2.

**Caso clínico:** varón de 57 años, con antecedentes de hipertensión controlada, acude al servicio de urgencias con ocho días de tos no productiva, asociada a un aumento subjetivo de la temperatura corporal. La exploración física al ingreso reveló taquipnea, fiebre de 38 °C, tensión arterial y frecuencia cardiaca normales; se realiza una radiografía de tórax que muestra neumonía grave, posteriormente evolucionó a insuficiencia ventilatoria que requirió manejo en unidad de cuidados intensivos para soporte con ventilación mecánica no invasiva. Infección por SARS-CoV confirmada con RT-PCR.

**Conclusión:** en este reporte presentamos un paciente con mielitis transversal concurrente a COVID-19, revisamos la literatura y discutimos los hallazgos clínicos e imagen dados por la enfermedad.

**Palabras Clave:** Covid-19; Mielitis transversa; Plasmaféresis.

## INTRODUCCIÓN

SARS-CoV-2, a single-stranded RNA-wrapped virus, has been identified since December 2020 as the cause of a heterogeneous disease known as Covid-19 disease that runs with a wide variety of clinical symptoms ranging from asymptomatic patients, mild respiratory conditions with symptoms such as fever and general malaise, up to severe manifestations that trigger multiorgan involvement and death (1).

Among the severe manifestations of the disease, in addition to the pulmonary and renal involvement of these patients, a proportion of cases with a broad neurological involvement have been described in the world literature. Although direct infection of the central nervous system is rare and of uncertain prognosis, and parainfectious complications such as inflammatory neuropathies are rare, critically ill patients often develop delirium and septic encephalopathy (2). On the other hand, decreased sense of smell and taste, and headache are very common in mild cases especially in young patients with a controlled immune response, while myalgias

and muscle involvement usually appear in immunocompromised patients.

Most neurological manifestations usually appear within a few days of starting the clinical symptoms, and start from mild involvement such as impaired sense of smell, to severe complications such as encephalopathy or delirium. Parainfectious complications at the neurological level have been described in the literature, however, the occurrence of inflammatory neuropathy during the acute course of the disease is rare.

In the literature, there are few reports of patients experiencing typical acute inflammatory demyelinating polyneuropathy during or after Covid-19 infection, with reported cases of acute polyradiculoneuritis with locked-in syndrome in a patient with Covid-19 (3) and another patient reported with acute motor sensory axonal neuropathy during the course of infection (4); the incidence of acute myelitis in the course of Covid-19 disease is unknown, with a scarce report of cases worldwide and there is, to this day, the discussion whether myelitis occurred directly from viral

infection or as an autoimmune sequel.

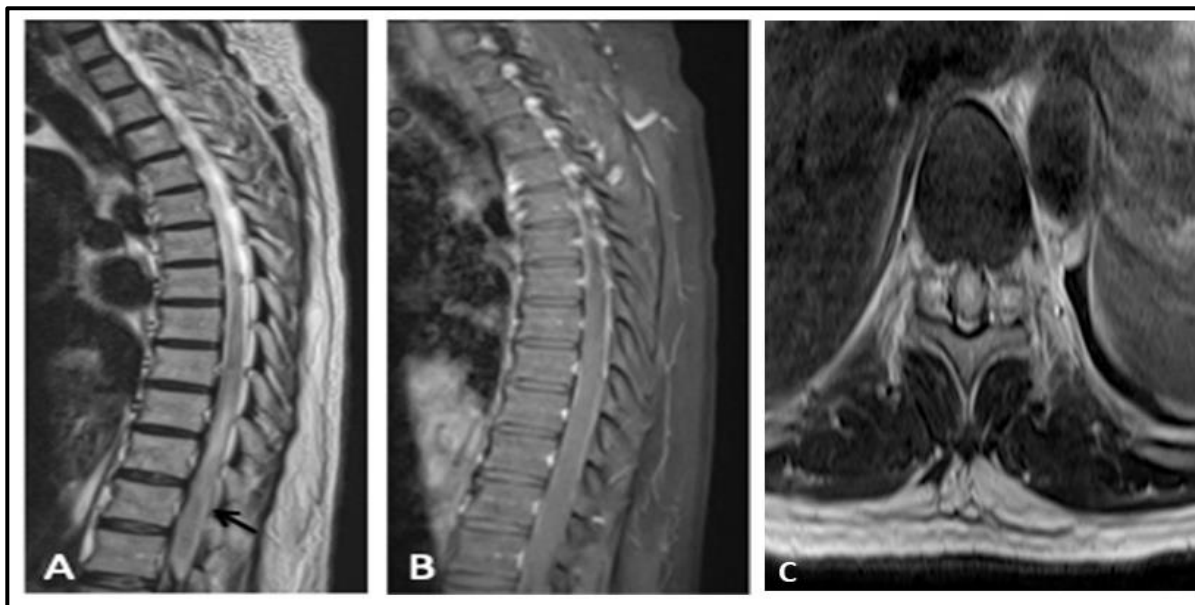
This is a case of a middle-aged man with a history of controlled hypertension who has a neurological impairment due to acute myelitis in the context of Covid-19 infection, treated with plasmapheresis and steroids with partial response to treatment.

### CLINICAL CASE

A 57-year-old man with a history of controlled hypertension, presented to the emergency department with eight days of non-productive cough, associated with a subjective increase in body temperature. Physical examination on admission revealed tachypnea, fever of 38°C, normal blood pressure and heart rate; a chest x-ray was performed that shows severe pneumonia, and later he progressed to ventilatory failure that required intensive care unit management for support with noninvasive mechanical ventilation. SARS-CoV2 infection confirmed with RT-PCR.

Antibiotic treatment was started concomitantly with non-invasive mechanical ventilation with a

stable evolution of symptoms. At 15 days of hospital stay, the patient reported intense low back pain, symmetrical difficulty walking, and sensation of paresthesias and dysesthesias in the lower extremities that progressed to the upper limbs in the next 48 hours. During the neurological examination, his mental status and cranial nerves were normal, tone and strength in the upper limbs was normal, and in the lower limbs strength was 0/5 proximally and distally with hypotonia. There was also hypotonia of the anal sphincter, neurogenic bladder, deep tendon reflexes ++/++++ in upper limbs and absent in the lower extremities, with bilateral mute plantar response. Abdominal skin reflexes and bulbocavernosus reflexes were absent. Sensory examination revealed an asymmetric T12 sensory level with apallesthesia in lower limbs. There were no meningeal signs. Differential imaging studies and complete metabolic profile were performed and, at the same time, intravenous methylprednisolone was given at a dose of 1 g for three days. An MRI of the thoracic and lumbosacral spine showed transverse myelitis from T8-T9 to the conus medullaris (Figure 1).



**Figure 1.** Magnetic resonance of lumbosacral spine. **A** Sagittal T2 sequence, shows longitudinally extensive myelitis with expansion and hyperintensity of the spinal cord, extending from T8-T9 to the conus medullaris (black arrow). **B**, Sagittal T1 contrasted with fat suppression sequence, without abnormal enhancement. **C**, T2 Axial sequence at the level of T10-T11, showing expansion of the spinal cord with holochroal hyperintensity, indicative of transverse myelitis.

As presumptive diagnosis transverse myelitis secondary to SARS-CoV-2 infection was considered, therefore, treatment with corticosteroids was started, however, given a poor response, it was decided to continue treatment with seven sessions of plasmapheresis and in the first five days a pulse of steroids. The patient presented a slight improvement with recovery of sensory deficits in the lower extremities. However, later he presented an extension of the spinal cord involvement with paraplegia, T6 sensitive level with neurogenic bladder and rectal atony.

## DISCUSSION

The variety of neurological symptoms described in Covid-19 are attributed to several mechanisms, some of which have been described in other viral infections; dissemination to the nervous system occurs directly through angiotensin-converting Enzyme 2 receptors (ACE2) expressed in the nasal epithelium or olfactory bulb through retrograde transsynaptic mechanisms, as well as through hematogenous and lymphatic migration of infected cells (5).

Neurological manifestations associated with SARS-CoV-2 infection have been described affecting the central and peripheral nervous system. A retrospective case series in China evidenced neurological alterations in 214 patients (6); headache, vertigo, impaired consciousness, ataxia, cerebrovascular disease, and epilepsy were the most common. Neurological manifestations were more common in the most critically ill patients (6). Acute necrotizing encephalitis, myelitis and variants of Guillain-Barre syndrome, such as axonal, demyelinating and Miller Fisher's syndrome have been reported (7-10).

The incidence of acute myelitis associated with Covid-19 infection is unknown. Similar cases have been reported in the literature linking Covid-19 to acute myelitis as a neurological complication. The

first was in Wuhan, where the first case was reported later in Boston (11, 12). Where the patient showed symptoms of upper respiratory tract infection and then developed acute myelitis 7 days later. However, it is still debatable whether myelitis occurred directly from the viral infection or as an autoimmune sequel; also another case of myelitis with concomitant manifestation of Guillain-Barre with acute necrotizing myelitis was reported recently (13). In our case it is considered a postinfectious myelitis since it occurred 23 days after the initial positive test.

In most of the cases described in the literature, the PCR of SARS-CoV-2 was positive in the nasopharyngeal aspirate as in our case, but negative in the cerebrospinal fluid (CSF) related to the unknown sensitivity of this test in the CSF. In our case one of the limitations is that we don't have CSF due to technical limitations for lumbar puncture (LP) after multiple attempts conditioning a post-traumatic hematoma.

The imaging of choice for the diagnosis of myelitis is MRI (14); the main sequences used are T2 and STIR (short-tau inversion recovery). MRI helps to exclude other etiologies such as compressive or ischemic in relation to the acute presentation of the condition.

The main findings are of central distribution and can extend one medullary segment or even more than 2 and be longitudinally extensive as the present case. The affected areas are shown to be hyperintense at T2 and STIR with variable contrast enhancement.

All patients described in the literature had an improvement after offering corticosteroids or plasmapheresis or a combination of both, thus demonstrating the usefulness of these therapies in the recovery of neurological conditions associated with SARS-CoV-2 infection, at least the ones mediated in an immunological way.

## CONCLUSIONS

Covid-19 disease is associated with multiple complications, including neurological. Transverse myelitis is infrequent; however, one must have a high index of suspicion to initiate early and timely treatment. More clinical characterizations of patients with Covid-19 and neurological complications are needed to clarify the true incidence of transverse myelitis in these types of patients.

**CONTRIBUTION OF THE AUTHORS:** NPG, RDA, VLM, ABE, MRS, NHB, MF, JRF, CSÁ: conception and design of the study, collection, analysis and interpretation of data, drafting of the article, critical revision and approval of the final version, responsible for the veracity and integrity of the article.

**FUNDING:** the present research has not received specific support from public sector agencies, commercial sector or non-profit entities.

**CONFLICTS OF INTEREST:** The authors declare no conflict of interest.

## REFERENCES

- Huang C, Wang Y, Li X, Ren L, Zhao J, Hu Y, et al. Clinical features of patients infected with 2019 novel coronavirus in Wuhan, China. *Lancet*. 2020; 17(2): 181-92. [https://doi.org/10.1016/S0140-6736\(20\)30183-5](https://doi.org/10.1016/S0140-6736(20)30183-5)
- Ahmad I, Rathore FA. Neurological manifestations and complications of COVID-19: A literature review. *Journal of Clinical Neuroscience*. 2020; 17(2): 181-92. <https://doi.org/10.1016/j.jocn.2020.05.017>
- Pfefferkorn T, Dabitz R, von Wernitz-Keibel T, Aufenanger J, Nowak-Machen M, Janssen H. Acute polyradiculoneuritis with locked-in syndrome in a patient with Covid-19. *Journal of Neurology*. 2020. <https://doi.org/10.1007/s00415-020-09897-y>
- Sedaghat Z, Karimi N. Guillain Barre Syndrome associated with COVID-19 infection: A case report. *J Clin Neurosci*. 2020; 17(2): 181-92. <https://doi.org/10.1016/j.jocn.2020.04.062>
- Berth SH, Leopold PL, Morfini GN. Virus-induced neuronal dysfunction and degeneration. *Front. Biosci. (Landmark Ed)* 2009; 14(14), 5239–5259. <https://doi.org/10.2741/3595>
- Mao L, Wang M, Chen Sh, He Q, Chang J, Hong C, et al. Neurological Manifestations of Hospitalized Patients with COVID-19 in Wuhan, China: A Retrospective Case Series Study (February 24, 2020). <https://doi.org/10.1001/jamaneurol.2020.1127>
- Sotoca J, Rodriguez-Alvarez. COVID-19-associated acute necrotizing myelitis. *Neurol Neuroimmunol Neuroinflamm* 2020; 7:e803. <https://doi.org/10.1212/NXI.0000000000000803>
- Poyiadji N, Shahin G, Noujaim D, Stone M, Patel S. COVID-19-associated acute hemorrhagic necrotizing encephalopathy CT and MRI features. *Radiology*. 2020; 6:97–123. doi:10.1148/radiol.2020201187
- Toscano G, Palmerini F, Ravaglia S et al. Guillain-Barré syndrome associated with SARS-CoV-2. *N Engl J Med*. 2020; 4:9 <https://doi.org/10.1056/NEJMc2009191>
- Gutiérrez-Ortiz C, Méndez A, Rodrigo-Rey S et al Miller Fisher syndrome and polyneuritis cranialis in COVID-19. *Neurology*. 2020; 7:16.
- Kang Zhao, Jucun Huang, Dan Dai, Yuwei Feng, Liming Liu, ShukeNiemedRxivAcute myelitis after SARS-CoV-2 infection: a case report. 2020; doi: <https://doi.org/10.1101/2020.03.16.2003510>
- Sarma, D., & Bilello, L. A. A Case Report of Acute Transverse Myelitis Following Novel Coronavirus Infection. *Clinical Practice and Cases in Emergency Medicine*. 2020; 17(2): 181-92. <https://doi.org/10.5811/cpcem.2020.5.47937>
- Maideniuc C, Memon A. Acute necrotizing myelitis and acute motor axonal neuropathy in a COVID-19 patient. *Journal of Neurology*. 2020; 17(2): 181-92. <https://doi.org/10.1007/s00415-020-10145-6>
- Scotti G, Gerevini S. Diagnosis and differential diagnosis of acute transverse myelopathy. The role of neuroradiological investigations and review of the literature. 2020; 17(2): 181-92. <https://doi.org/10.1007/s100720100038>