



ACCESO  ABIERTO

Para citaciones: Benedetti, I., Lecompte, P., Barrios, L. (2021). Expression of Osteopontin and Cyclooxygenase-2 in relation to cellular proliferation, in non-tumor colonic mucosa, colonic adenomas and colon adenocarcinoma. *Revista Ciencias Biomédicas*, 10(1), 3-15.

Recibido: 22 de octubre de 2020
Aprobado: 20 de diciembre de 2020

Autor de correspondencia:

Inés Benedetti
ebenedettip1@unicartagena.edu.co

Editor: Inés Benedetti. Universidad de Cartagena-Colombia.

Copyright: © 2021. Benedetti, I., Lecompte, P., Barrios, L. Este es un artículo de acceso abierto, distribuido bajo los términos de la licencia <https://creativecommons.org/licenses/by-nc-sa/4.0/> la cual permite el uso sin restricciones, distribución y reproducción en cualquier medio, siempre y cuando el original, el autor y la fuente sean acreditados.



Expression of Osteopontin and Cyclooxygenase-2 in relation to cellular proliferation, in non-tumor colonic mucosa, colonic adenomas and colon adenocarcinoma

Expresión de Osteopontina y Ciclooxygenasa-2 en relación con la proliferación celular, en mucosa colónica no tumoral, adenomas y adenocarcinoma de colon

Inés Benedetti¹ , Paola Lecompte² , Lía Barrios³ 

¹ Departamento de Ciencias Básicas, Grupo de investigación Histopatología, Facultad de Medicina, Universidad de Cartagena, Colombia.

² Grupo de investigación Histopatología, Facultad de Medicina, Universidad de Cartagena, Colombia.

³ Grupo de investigación Histopatología, Facultad de Medicina, Universidad de Cartagena, Colombia.

ABSTRACT

Introduction: the participation of Cyclooxygenase-2 (COX-2) and Osteopontin has been postulated in the development of colon cancer, which play an important role in the progression and could be biomarkers for its prognosis, but their role remains controversial.

Objective: to determine and to compare the expression of Osteopontin and COX-2 in non-tumor colonic mucosa, colonic adenomas and colon adenocarcinoma, in relation to the cell proliferation index.

Methods: the immunohistochemical expression of COX-2, Osteopontin and Ki-67 in formalin fixed paraffin embedded tissue of non-tumor colonic mucosa, colonic adenomas and colon adenocarcinoma were determined and compared.

Results: were included 65 cases: 19 of non-tumor colonic mucosa, 13 colonic adenomas and 33 colon adenocarcinomas. There was increased expression of Ki-67 in dysplastic and tumor cells. There was positive expression for COX-2 in adenomas (30.7%) and adenocarcinomas (27.3%), without significant difference between non-tumor colonic mucosa, adenomas and adenocarcinoma ($p = 0.888$). Osteopontin showed more frequent positivity in adenocarcinomas (72.7%) and adenomas (84.6%) than in non-tumor mucosa (10.5%), ($p = <0.0001$), without significant differences in its expression between subtypes and grades of adenoma dysplasia, nor between grades of differentiation, extension and proliferation of adenocarcinomas. There was a significant association between Osteopontin expression and the cell proliferation index. No association was observed between the expression of COX-2 and Osteopontin ($p = 0.96$).

Conclusions: Osteopontin overexpression in colon adenocarcinoma and adenomas in comparison with non-tumor colonic mucosa, and its significant relationship with the cell proliferation index, constitutes additional evidence of its possible participation in the colonic carcinogenesis process.

Keywords: Colorectal cancer; Osteopontin; Cyclooxygenase-2.

RESUMEN

Introducción: se ha postulado la participación de Ciclooxygenasa-2 (COX-2) y Osteopontina en el desarrollo del cáncer de colon, las cuales juegan un papel importante en la progresión tumoral y podrían ser biomarcadores de pronóstico, pero su papel sigue siendo controvertido.

Objetivo: determinar y comparar la expresión de Osteopontina y COX-2 en mucosa colónica no tumoral, adenomas colónicos y adenocarcinoma de colon, en relación con el índice de proliferación celular.

Métodos: se determinó y comparó la expresión inmunohistoquímica de COX-2, Osteopontina y Ki-67 en tejido incluido en parafina de mucosa colónica no-tumoral, adenomas colónicos y adenocarcinomas de colon.

Resultados: se estudiaron 65 casos: 19 mucosas colónicas no-tumorales, 13 adenomas y 33 adenocarcinomas. Hubo sobreexpresión de Ki-67 en células displásicas y tumorales. Se encontró expresión positiva para COX-2 en adenomas (30.7%) y adenocarcinomas (27.3%), sin diferencia significativa entre mucosa colónica no-tumoral, adenomas y adenocarcinomas ($p=0.888$). Osteopontina mostró positividad más frecuente en adenocarcinomas (72.7%) y adenomas (84.6%) que en mucosa no-tumoral (10.5%), ($p<0.0001$); sin diferencias significativas entre subtipos y grados de displasia de adenomas, ni entre grados de diferenciación, extensión y proliferación de adenocarcinomas. Hubo asociación significativa entre expresión de Osteopontina y el índice de proliferación celular. No se observó asociación entre la expresión de COX-2 y de Osteopontina ($p=0.96$).

Conclusiones: la sobreexpresión de Osteopontina en adenocarcinoma de colon y adenomas en comparación con la mucosa colónica no-tumoral, y su relación significativa con el grado de proliferación celular, constituye evidencia adicional de su posible participación en el proceso de la carcinogénesis colónica.

Palabras Clave: Cáncer colorrectal; Osteopontina; Ciclooxygenasa-2.

INTRODUCTION

Colon cancer is one of the most common malignancies worldwide, in 2018, with an age-standardized rate of 11.1 per 100,000 person-years, ranked fourth in the estimated cancer incidence rates; being the fourth more frequently presented in women and the sixth in men, also worldwide (1). The prognosis of colon cancer is related to the pathological stage at diagnosis, with 5-year survival ranging from 74% for stage I to 5.7% for stage IV (2).

The vast majority of colon cancers correspond to adenocarcinomas, of which a high percentage develops sporadically, while the rest originates in subjects to known family history (3, 4). Colon

carcinoma is caused by mutations in oncogenes, tumor suppressor genes, and DNA repair genes (5-7); depending on the origin of the mutation, it is classified as sporadic (70%); hereditary (5%), or familial (25%) (5). The colorectal mucosa gives rise to an adenocarcinoma following a progressive sequence of healthy mucosa-adenoma-carcinoma (6, 8). Genomic changes include the activation of proto-oncogenes (*K-Ras*) that occur in 30% to 40% of cases (7), and the inactivation of at least three tumor suppressor genes: loss of *APC* (chromosome region 5q21), loss of *p53* (chromosome region 17p13), and loss of heterozygosity for the long arm of chromosome 18 (18q LOH). Mutations involving other genes, such as *TGFBR* and *PIK3CA*, that are required for the adenoma-carcinoma sequence model have been described; *APC* is the most commonly

mutated initial gene in familial/hereditary and sporadic colon cancer (6).

In the prevention of colon cancer, one of the most discussed points has been the possible reduction of cases in patients who use chronic nonsteroidal anti-inflammatory drugs (NSAIDs), they exert their effect by intervening in the conversion of arachidonic acid into prostaglandins by inhibiting the isoforms of cyclooxygenases (COX1 and COX2). Increased expression of these enzymes has been shown as the dysplasia-adenoma-carcinoma sequence advances, which has been reported as evidence of their involvement in the development of this disease (9-11). Another protein that plays an important role in the progression of cancer, and is considered as a possible biomarker for its prognosis is Osteopontin, an integrin-binding glycosphoprotein encoded by the *SPP1* gene (12-14), which is highly expressed in colon cancer cells or tissues compared to intestinal epithelial cell lines and benign colonic tissues (15). It has been described that the increased expression of Osteopontin through some signaling pathways leads to overexpression of COX-2 and production of prostaglandins E2 (PGE2) by tumor macrophages in melanoma (16) and to production and activation of matrix-2 metalloproteinase (MMP-2) in high-grade prostate cancer, which leads to angiogenesis and regulates tumor progression (17).

To evaluate whether there is a relationship between the expression of these proteins and the tissue that represents the steps in the development of colon cancer, the objective of this study was to determine the expression of Osteopontin and COX-2 in samples of nontumor colonic mucosa, colonic adenomas, and colon adenocarcinoma, and compare them with the cell proliferation observed in each of them, allowing to explore this possible molecular alternative in the study of this pathology.

METHODS

A descriptive study was conducted at the Faculty of Medicine of the University of Cartagena and the University Hospital of the Caribbean, in

Cartagena, Colombia. The study was approved by the Ethics Committees of the participating institutions. The database of the Pathology Laboratory of the University Hospital of the Caribbean was reviewed, from which were selected cases with diagnoses of: healthy colorectal mucosa, adenoma, and colon adenocarcinoma studied during a period of six months, with formalin fixed paraffin-embedded (FFPE) tissues. Two pathologists evaluated the histological slides stained with Haematoxylin-Eosin to select representative tissue samples from each of the categories to be studied, and assign each sample within one of the following three groups: healthy colonic mucosa, adenoma, and colon adenocarcinoma. The clinical-pathological information of the cases was obtained including: age, sex, type of adenoma and grade of dysplasia, and, differentiation and extent of adenocarcinoma cases. Subsequently, the expression of the COX2 and Osteopontin proteins and the Ki67 cell proliferation marker were determined in the samples included in the study, using immunohistochemical assays, the results of which were evaluated and compared between the established groups.

Immunohistochemistry assays and analysis

Three new sections were made to each of the selected FFPE tissue blocks, which were subjected to immunohistochemistry tests with each of the markers under study. The assays were performed in the Laboratory of Histotechnology of the faculty of Medicine of the University of Cartagena, under the routine protocol, briefly: sections were deparaffinized in xylol and dehydrated in alcohol, subjected to antigen recovery in 10 mM citrate buffer at 90°C, subsequently covered with Hydroxygen Peroxide Block, and Ultra V Block, then 100 µl of each of the primary antibodies were added to each section: COX2: Clone SP21 rabbit monoclonal antibody, (Thermo Scientific®, Whaltam, MA, U.S.A.); Osteopontin: rabbit polyclonal antibody, (Thermo Scientific®, Whaltam, MA, U.S.A.) and incubated for 30 minutes at room temperature; while the primary antibody Ki67: rabbit monoclonal antibody, (Thermo Scientific®, Whaltam, MA, U.S.A.), was incubated overnight at 4°C. Subsequently, the sections were incubated for

30 minutes at room temperature with the secondary antibody UltraVision ONE HRP Polymer (Thermo Scientific®, Whaltam, MA, U.S.A.); the visualization of the reaction was carried out using DAB Plus Chromogen, (Thermo Scientific®, Whaltam, MA, U.S.A.), and the sections were contrasted with hematoxylin; for all the assays the commercial kit Ultravision ONE Detection System, HRP Polymer & DAB Plus Chromogen, (Thermo Scientific®, Whaltam, MA, U.S.A.) was used.

The evaluation of immunohistochemistry was performed blindly by two pathologists who analyzed the percentage of positive cells for each of the markers, as well as the staining intensity in relation to the cell types and their location in the tissue, according to the parameters established for each one of them. The analysis was carried out at a final magnification of 100X and 400X using an Eclipse microscope 400® connected to a DSFi1® camera (Nikon, Japan), and the intensity of the staining was measured using the NIS-Elements-3.0® program (Nikon, Japan).

For the immunohistochemical analysis of COX-2, the point scale proposed by Soslow was applied, according to which, depending on the percentage of positive cells, it was classified on a quantitative percentage scale of 0-4 (11), and depending on the intensity of the stain on a quantitative intensity scale of 0-3 (11). Both scales converge in the German ImmunoReactive Score, according to which, the result of the quantitative scales of percentage and intensity of expression was multiplied to classify in a scale of 0-12 points, in addition, the expression by location was documented using a scale proposed by Wasilewicz (18) of 1-3 (12). The Osteopontin expression was considered positive when there was an evident yellowish-brown staining at the cytoplasmic level in more than >10% of the evaluated cells (19). The evaluation of the immunohistochemical staining for Ki-67 was performed based on the method of Petrisor et al (20) according to which the microscopic field was divided into four quadrants by imaginary lines, in each quadrant a random count of one hundred cells was made, from which the percentage of positive

cells was obtained and an average representing the score of cell proliferation was obtained (14). The cell proliferation index was considered high when it was 50%, medium if it was between 20% - < 50%, and low when it was < 20%.

Statistical Analysis

The data were recorded in a Microsoft Excel® database (Microsoft, Redmond, WA, U.S.A.). The associations between the expression of COX2, Osteopontin and Ki67 were determined between the groups of tissues with healthy colonic mucosa, adenoma, and colon adenocarcinoma, and in relation to the clinical-pathological variables, by performing Chi square tests, Student t test and ANOVA test, depending on the type of variable and the groups compared. For all analyses, GraphPad Prism® v 8.0 software (San Diego, CA, U.S.A.) was used, a value of $p < 0.05$ was considered statistically significant.

RESULTS

A total of 65 cases with colonic tissue samples were included, 19 of them corresponding to non-tumor colonic mucosa, 13 cases of adenomas and 33 cases of infiltrating adenocarcinoma. Among the cases of non-tumor colonic mucosa, 9 (47.3%) corresponded to colonic mucosa neighboring an adenocarcinoma. The cases of colonic adenoma corresponded to patients with mean age of 70.15 years ($SD = \pm 12.79$), 13 women (76.9%) and 3 men (23.1%). They included: 6 tubular adenomas, four of them with mild dysplasia, one with moderate dysplasia and one with severe dysplasia, and 7 tubular-villous adenomas of which 1 had mild dysplasia, 3 had moderate dysplasia and 3 had severe dysplasia.

In the group of adenocarcinoma cases, the mean age of the patients was 56.5 years ($SD = \pm 14.73$), 13 (39.4%) were female and 20 (60.6%) were male. They included 12 (36.3%) well-differentiated adenocarcinomas, 16 (48.5%) moderately differentiated adenocarcinomas, and 5 (15.2%) poorly differentiated adenocarcinomas. As for the extent of the tumor, all cases of adenocarcinoma had infiltration beyond the submucosa, limited to the muscle layer in 3 (9%) cases, with involvement up

to the serosa in 7 (21.3%) cases, with extension to the pericolonic tissue in 15 (45.5%) cases, and, with pericolonic lymph node involvement in 8 (24.2%) cases.

The cell proliferation index with the Ki-67 antibody was significantly higher in cases of adenoma and adenocarcinoma than in the non-tumor colonic mucosa; a high percentage was found in tumor cells and dysplastic cells compared to normal crypts, where it was increased only at the base level. A cell proliferation index greater than 50% was found in 41.9% (n=13) of adenocarcinoma cases, with a statistically significant difference (<0.0001) between the different tissue types studied (Table 1), (Figure 1). In two cases of adenocarcinoma, it was not possible to evaluate the cell proliferation index, due to the depletion of tumor tissue in the new sections.

Positive staining for COX-2 was cytoplasmic and granular. In all cases of non-tumor colonic mucosa, some grade of positivity to the expression of COX-2 was found in epithelial cells, being mild and focal in most of them, and intense in only 3 (15.7%) cases; in addition, occasional mild expression of COX-2 was observed in inflammatory and stromal cells adjacent to the epithelium. No greater expression of COX-2 was found in the healthy peritumoral mucosa, compared to the healthy non-peritumoral mucosa.

In cases of adenoma and adenocarcinoma, positive expression for COX-2 was observed in 30.7% and 27.3%, respectively, being intense and positive in more than 75% of the cells in 8 (24.2%) cases of adenocarcinoma, and in 4 (30.7%) cases of adenoma, compared with only two cases of non-tumor mucosa with this same pattern of COX-2 expression (Figure 2). The expression of COX2 was localized at the level of epithelial and tumor cells in all cases of adenoma and adenocarcinoma, respectively, being also expressed at the stromal level in one of the cases of adenocarcinoma.

In several adenocarcinoma cases, a marked contrast was observed between the intensely positive expression of COX-2 in tumor cells, compared to the absent or weak expression in the neighboring non-tumor mucosa. (Figure 2). However, no significant difference was found in the immunohistochemical expression of COX-2 between non-tumor colonic mucosa, adenomas and colonic adenocarcinomas (p=0.888, ANOVA), nor, between the subtypes and grades of dysplasia of the adenomas, or between the different grades of differentiation and extent of adenocarcinoma cases (Table 2). Although a high cell proliferation index was found in all cases of adenocarcinoma with strong expression of COX-2, there was no significant difference in the level of expression of COX-2 between tumors with different grades of cell proliferation (p= 0.73, t-test), (Table 2).

Table 1. Cell proliferation index by tissue type

Cell proliferation index	Non-tumor colonic mucosa n (%)	Adenoma n (%)	Adenocarcinoma n (%)	P Value
High: ≥ 50%	0 (0%)	3 (23.1%)	13 (41.9%)	
Medium: >20% - < 50%	1(5.3%)	9 (69.2%)	18 (58.1%)	<0.0001*
Low: ≥ 20%	18 (94.7%)	1(7.7%)	0 (0%)	
Total	19	13	31	

* Chi square test

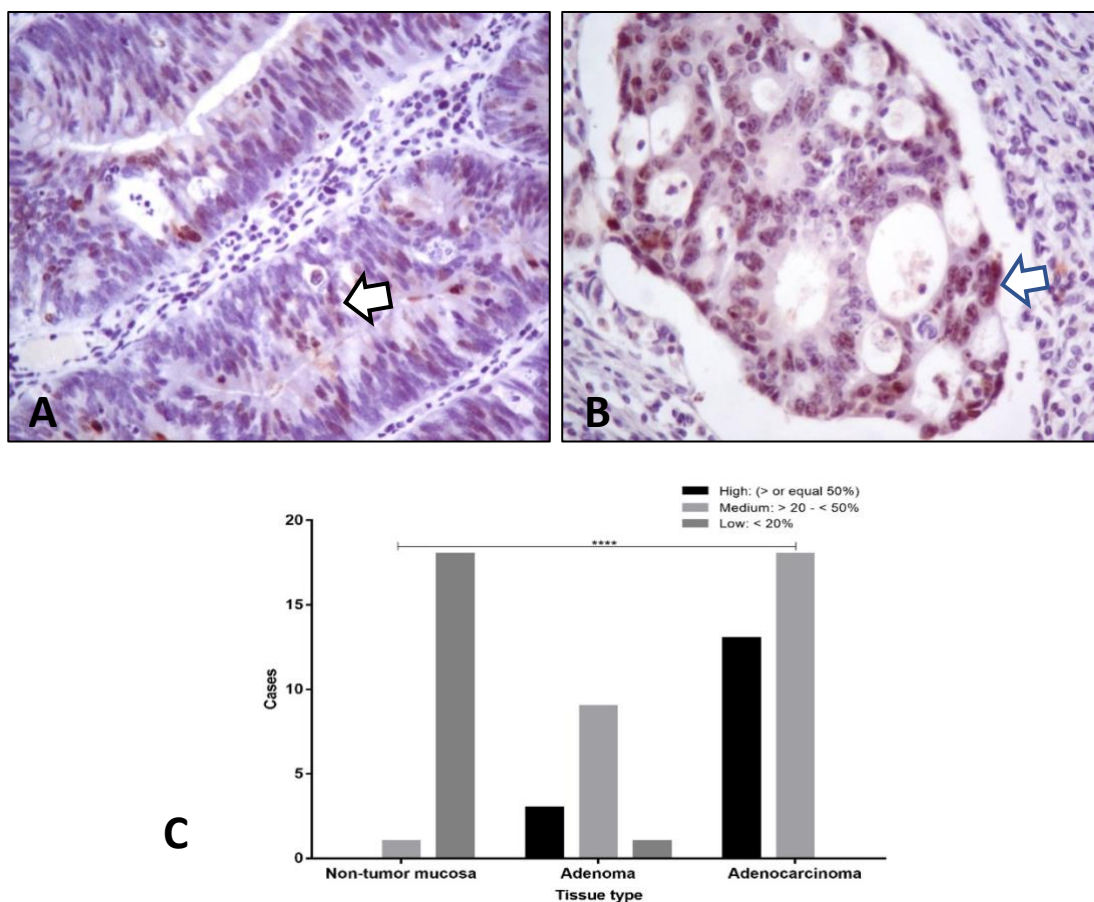


Figure 1. A, B: Histological slices of well-differentiated adenocarcinomas with nuclear positivity for Ki-67 (brown staining, arrows) (IHQ, Ki-67 antibody, 40X). C. Cell proliferation index in different tissue types (ANOVA).

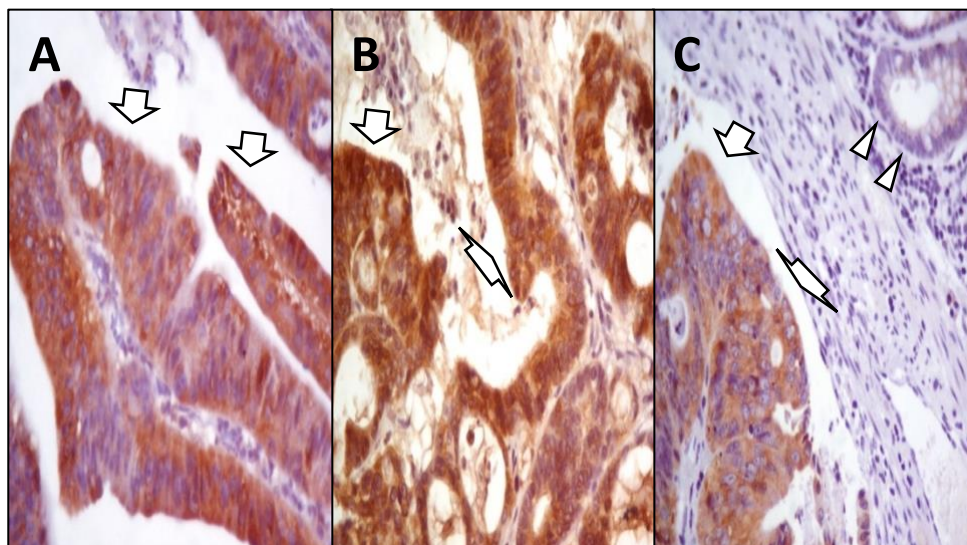


Figure 2. A. Tubulo-villous adenoma, positive for COX-2 at epithelial level (arrows). B. Well-differentiated adenocarcinoma, positive for COX-2, (arrows). C. Positive staining for COX-2 in tumor cells (arrows) compared to negative staining in neighboring non-tumor colonic mucosa (arrowheads), (IHQ, COX-2 antibody, 40X).

Osteopontin showed a cytoplasmic staining pattern, being its positivity more frequent in cases of adenocarcinoma (72.7%) and adenomas (84.6%) than in cases of non-tumor mucosa (10.5%), with a significant association between its expression and the type of tissue ($p < 0.0001$, Chi square), (Table 3); (Figure 3). No significant differences were found in the expression of Osteopontin between the subtypes and grades of dysplasia of the adenomas, nor between the grades of differentiation, extension and

proliferation of cases of adenocarcinoma, (Table 3). However, there was a significant association between the expression of Osteopontin and the cell proliferation index for all types of tissues (Table 4). In two of the Osteopontin-positive adenocarcinoma cases, it was not possible to evaluate the cell proliferation index due to tissue depletion. No significant association was found between COX-2 expression and Osteopontin expression (Table 5).

Table 2. COX-2 expression in non-tumor colonic mucosa, adenomas and colon adenocarcinomas

	COX-2 expression		p Value
	n (%)	Media (\pm DE)	
Non-tumor mucosa	19 (29.2%)	6.73 (\pm 2.6)	0.888*
Adenoma	13 (20%)	7.31 (\pm 3.8)	
Adenocarcinoma	33 (50.7%)	6.97 (\pm 3.3)	
Adenomas, subtype			
Tubular	6 (46.2%)	5.5 (\pm 2.6)	0.116 [†]
Tubulo villous	7 (53.8%)	8.8 (\pm 4.1)	
Adenomas, grade of dysplasia			
Mild dysplasia	5 (38.4%)	7 (\pm 4)	0.179*
Moderate dysplasia	4 (30.8%)	5 (\pm 2)	
Severe dysplasia	4 (30.8%)	10 (\pm 4)	
Adenocarcinomas, differentiation			
Well differentiated	12 (36.4%)	6.66 (\pm 3.6)	0.479*
Moderately differentiated	16 (48.5%)	7.62 (\pm 3.6)	
Poorly differentiated	5 (15.1%)	5.6 (\pm 0.8)	
Adenocarcinomas, extension			
Outer muscular layer	3 (9.1%)	4.66 1.1)	0.649*
Serosa	7 (21.3%)	7.42 (\pm 3.5)	
Pericolonic tissue	15 (45.41%)	7.93 (\pm 3.7)	
Neighboring lymph nodes	8 (24.2%)	7.5 (\pm 2.9)	
Adenocarcinomas, cellular proliferation index			
High (\geq 50%)	13 (41.9%)	6.84 (\pm 3.1)	0.735 [†]
Low (< 50%)	18 (58.1%)	7.27 (\pm 3.7)	

* ANOVA, [†] t Test.

Table 3. Osteopontin expression in non-tumor colonic mucosa, adenomas and colon adenocarcinomas

	Osteopontin expression		p Value
	n (%)		
	Positive	Negative	
Non-tumor mucosa	2 (10.5%)	17 (89.5%)	
Adenoma	11 (84.6%)	2 (15.4%)	<0.0001*
Adenocarcinoma	24 (72.3%)	9 (27.7%)	
Adenomas, subtype			
Tubular	5 (83.3%)	1 (16.7 %)	>0.9999 [†]
Tubulo-villous	6 (85.7%)	1 (14.3%)	
Adenomas, degree of dysplasia			
Low dysplasia	4 (80 %)	1 (20 %)	>0.9999 [†]
Moderate/ severe dysplasia	7 (87.5%)	1 (12.5%)	
Adenocarcinomas, differentiation			
Well differentiated	7 (58.3%)	5 (41.7%)	0.1807*
Moderately differentiated	14 (87.5%)	2(12.5%)	
Poorly differentiated	3 (60 %)	2 (40 %)	
Adenocarcinomas, extension			
Muscular layer / serosa	9 (81.8%)	2 (18.2%)	0.5971*
Pericolonic tissue	10 (66.6%)	5 (33.4%)	
Neighboring lymph nodes	5 (62.5%)	3 (37.5%)	
Adenocarcinomas, cellular proliferation index			
High (≥ 50%)	12 (92.2%)	1 (7.8%)	0.0448 [†]
Low (< 50%)	10 (55.6%)	8(44.4%)	

*Chi square, [†] Fisher test

Table 4. Immunohistochemical expression of Osteopontin in relation to cell proliferation index in all types of tissues studied

Cellular proliferation index	Osteopontin expression		p Value
	n (%)		
	Positive	Negative	
High: greater than or equal to 50%	14 (38.8%)	2 (6.9%)	<0.0001*
Medium:: ≥20 – less than a 50%	20 (55.5 %)	10(34.5%)	
Low: less than 20%	2 (5.5 %)	17(58.6%)	
Total	36	29	

* Chi square test

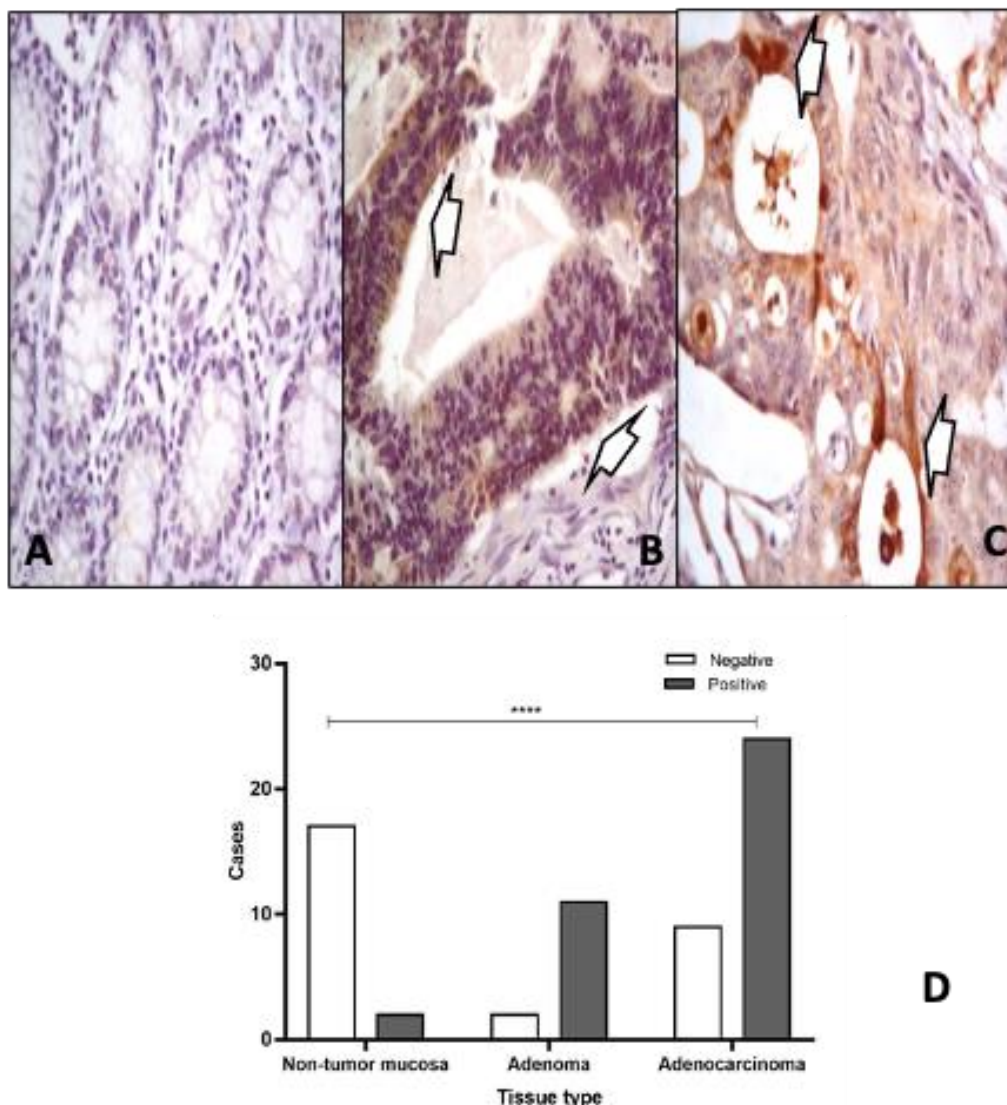


Figure 3. A. Non-tumor colonic mucosa, negative for Osteopontin. B. Tubulo-villous adenoma, positive for Osteopontin at epithelial level, (arrows). C. Well-differentiated adenocarcinoma, positive for Osteopontin, (arrows), (IHQ, Osteopontin antibody, 40X). D. Osteopontin expression in different tissue types (Chi square).

Table 5. Immunohistochemical expression of Osteopontin in relation to COX-2 expression

COX-2 Expression	Osteopontin expression		p Value
	n(%)		
	Positive	Negative	
Strong	9(24.3 %)	7 (25%)	0.96*
Moderate	19 (51.4 %)	15(53.6%)	
Weak	9(24.3%)	6 (21.4%)	
Total	36	28	

* Chi square test

DISCUSIÓN

Non-tumor colonic mucosa tissues, adenomas and colon adenocarcinomas were analyzed to evaluate the expression of the COX2 and Osteopontin biomarkers in relation to proliferative activity using Ki-67, a monoclonal antibody directed at a nuclear antigen expressed in proliferating cells (21). As described by several studies, a high cell proliferation index was found in all cases of colon adenocarcinoma (20, 22-24); while in the adenomas the distribution pattern for Ki-67 showed expression beyond the crypt bases, similar to previously reported by Torlakovic et. al. (25)

Cyclooxygenase or prostaglandin synthase, has two isoenzymes, COX-1 is the constitutive isoform normally present in the organs, and COX-2 is induced in a limited number of organs, by cytokines, growth factors, hormones and carcinogens. It has been stated that the expression of COX-1 in colon cancer does not differ from its expression in non-tumor colonic mucosa, while the expression of COX-2 is significantly higher in this neoplasm (9, 10, 26, 27). However, these findings are controversial, while some studies suggest a relationship between COX-2 expression and colon cancer (28), others find no evidence of such a relationship (29, 30), which is consistent with the findings of this study in which no significant difference was found between its expression and the type of colonic tissue studied (non-tumor colonic mucosa, adenomas, and colon adenocarcinoma).

COX-2 expression was found in healthy colonic mucosa, with weak positivity for this marker in a high percentage of non-tumor epithelium samples not associated with neighboring tumor lesion, but was often associated with acute and chronic inflammatory infiltrate in the surrounding lamina propria, so that mild expression of the enzyme in the non-tumor mucosa could be attributed to the inflammatory component present in those tissues, according to the established relationship between increased expression of COX-2 and inflammatory processes (31). Mild positivity to COX-2 was also detected in most of the samples of peritumoral tissue

studied, without it being greater than that found in the healthy non-peritumoral mucosa, unlike that described by Soslow et. al., who found a higher expression of COX-2 in the tissue neighboring the tumor and suggested a paracrine-type field effect, raising the possibility of an increased risk of developing further neoplasms in these tissues. This, possibly originating in the effect of prostaglandins produced by COX-2-positive tumor cells, as positive modulators of the interaction between transformed cells and the activation of stromal elements, necessary for tumor growth and invasion capacity (11).

There was no association between the expression of COX-2 and the cell proliferation index, a similar finding to that described by Sakuma et. al., who compared COX-2 and Ki67 in human colon cancer without finding a correlation in their expression, suggesting that the enzyme has no effect on cell proliferation and that despite playing an important role in carcinogenesis, its effects on tumor growth are unclear (26).

On the other hand, Osteopontin plays an important role in tissue homeostasis, with diverse biological functions such as regulation of the immune response, bone resorption, wound healing, and cellular adhesion to the extracellular matrix (13, 32). Its expression has been described as associated with tumorigenesis, as well as the progression and metastasis of malignant tumors of the breast, lung, prostate, pancreas, and colon (33). Elevated circulating levels of this protein have been reported in colon cancer (34), and its overexpression has been found to correlate with poor prognosis and reduced survival (13, 33). It has been described that the low expression of Osteopontin can suppress tumorigenicity, while its overexpression induces cell survival, early metastasis, and resistance to chemotherapy (35). This study showed overexpression of Osteopontin in cases of colon adenocarcinoma compared to healthy mucosa, a result similar to that reported in other studies (19, 34) such as that of Li et. al., who in a sample of 77 patients with colon cancer found increased expression of Osteopontin in 49.4% of cases (19),

and to the study carried out by Youseff et. al., where 72 cases of colon cancer were evaluated, finding overexpression of Osteopontin in 45.8% of them (36), highlighting that in the present study the overexpression of Osteopontin was found in a much greater percentage of the adenocarcinoma cases.

In the study by Cheng et. al., in patients with colorectal carcinoma, Osteopontin expression levels were higher in tumor tissue than in benign tissue. As in this work, this difference in expression was maintained between tumors of different sizes and grades of differentiation and extension, however, unlike what was found in the present study, they reported that the expression of Osteopontin was positively correlated with the presence of nodal involvement and with the clinical-pathological stage (37); showing clear evidence of the involvement of this protein in the migration and invasion of tumor cells by triggering a response leading to the activation of the PI3K-AKT-GSK/3b-b/catenin signaling pathway, and postulate it as a possible therapeutic target for and prevention of metastasis in the progression of this neoplasm (37).

Osteopontin regulates tumor growth, angiogenesis, and metastasis, and induces relapses through multiple signaling pathways; one of these is specifically observed in the tumor microenvironment, where it induces the secretion of COX-2 and PGE2 facilitating motility of tumor cells and angiogenesis (17, 35), it has also been reported that in prostate cancer Osteopontin plays an important role in the activation of MMP-2 by tumor cells that regulates tumor progression (17). In melanoma, tumor infiltration by macrophages positive for Osteopontin and COX-2 has been reported to correlate with angiogenesis and increased tumor growth (16). In this study, no association was found between overexpression of Osteopontin and COX-2 in tumor tissue.

A limitation of this study is the number of samples studied; another could be having included adenomas with different grades of dysplasia, however, the results obtained between them were compared when

performing analysis between the subgroups, without finding significant differences.

In conclusion, the present study provides evidence of overexpression of Osteopontin in colon cancer and colonic adenomas compared to the non-tumor colonic mucosa, and in relation to the cell proliferation index in premalignant and malignant lesions of the colon, in human tissues. These findings are additional evidence of their possible involvement in the process of colonic carcinogenesis.

FUNDING: This study was financed to the Histopathology group by the University of Cartagena, favored in the fourth call for the financing of research projects, for the research groups classified by Colciencias and endorsed by the University of Cartagena, Colombia.

ACKNOWLEDGMENTS: The authors are thankful to the Department of Pathology of the Hospital Universitario del Caribe, Cartagena, Colombia, for providing the tissue samples.

REFERENCES

1. Ferlay J CM, Soerjomataram I, Mathers C, Parkin DM, Piñeros M, Znaor A, Bray F. Estimating the global cancer incidence and mortality in 2018: GLOBOCAN sources and methods. *Int J Cancer*. 2019;144(8):1941-53.
2. Campo-Sánchez S, Camargo-Trillos J, Calle-Ramírez J, Gómez-Wolff L, Sánchez-Patiño L, García-García H. Supervivencia de cáncer colorrectal en un centro oncológico de Colombia. Estudio de cohorte histórica. *Revista de Gastroenterología de México*. 2018.
3. Giráldez MD. Avances en la etiopatogenia, identificación y manejo clínico de las formas hereditarias y familiares de cáncer colorrectal. *Gastroenterología y Hepatología*. 2011;34:70-5.
4. Fearon ER, Vogelstein B. A genetic model for colorectal tumorigenesis. *Cell*. 1990;61(5):759-67.
5. Marmol I, Sanchez-de-Diego C, Pradilla Dieste A, Cerrada E, Rodriguez Yoldi MJ. Colorectal Carcinoma:

- A General Overview and Future Perspectives in Colorectal Cancer. *Int J Mol Sci.* 2017;18(1).
6. Armaghany T, Wilson JD, Chu Q, Mills G. Genetic alterations in colorectal cancer. *Gastrointestinal cancer research: GCR.* 2012;5(1):19.
 7. Niitsu H, Hinoi T, Kawaguchi Y, Sentani K, Yuge R, Kitadai Y, et al. KRAS mutation leads to decreased expression of regulator of calcineurin 2, resulting in tumor proliferation in colorectal cancer. *Oncogenesis.* 2016;5(8):e253.
 8. Leslie A, Carey F, Pratt N, Steele R. The colorectal adenoma–carcinoma sequence. *British Journal of Surgery.* 2002;89(7):845-60.
 9. Benedetti-Padrón I, Becerra-Mejía D. Expresión de Ciclooxygenasa-2 en carcinoma colorrectal, una revisión narrativa. *Iatreia.* 2019;32(1):52-63.
 10. Koehne C-H, Dubois RN, editors. COX-2 inhibition and colorectal cancer. *Seminars in oncology;* 2004: Elsevier.
 11. Soslow RA, Dannenberg AJ, Rush D, Woerner B, Khan KN, Masferrer J, et al. COX-2 is expressed in human pulmonary, colonic, and mammary tumors. *Cancer.* 2000;89(12):2637-45.
 12. Di Bartolomeo M, Pietrantonio F, Pellegrinelli A, Martinetti A, Mariani L, Daidone MG, et al. Osteopontin, E-cadherin, and β -catenin expression as prognostic biomarkers in patients with radically resected gastric cancer. *Gastric cancer.* 2016;19(2):412-20.
 13. Wei R, Wong JPC, Lyu P, Xi X, Tong O, Zhang SD, et al. In vitro and clinical data analysis of Osteopontin as a prognostic indicator in colorectal cancer. *Journal of Cellular and Molecular Medicine.* 2018;22(9):4097-105.
 14. Becerra D, Benedetti I. OSTEOPONTINA, UNA PROTEÍNA INVOLUCRADA EN LA PROGRESIÓN TUMORAL, Y SU PARTICIPACIÓN EN EL DESARROLLO DEL CARCINOMA COLORRECTAL. *Revista Ciencias Biomédicas.* 2019;8(1):15-21.
 15. Zubiaurre L, de Pierola LBF. Aspirina en la prevención del cáncer colorrectal. *Gastroenterología y Hepatología.* 2011;34(5):337-45.
 16. Kale S, Raja R, Thorat D, Soundararajan G, Patil TV, Kundu GC. Osteopontin signaling upregulates cyclooxygenase-2 expression in tumor-associated macrophages leading to enhanced angiogenesis and melanoma growth via α 9 β 1 integrin. *Oncogene.* 2014;33(18):2295-306.
 17. Jain S, Chakraborty G, Kundu GC. The crucial role of cyclooxygenase-2 in osteopontin-induced protein kinase C α /c-Src/IkappaB kinase α /beta-dependent prostate tumor progression and angiogenesis. *Cancer Res.* 2006;66(13):6638-48.
 18. Wasilewicz MP, Kołodziej B, Bojułko T, Kaczmarczyk M, Sulzyc-Bielicka V, Bielicki D. Expression of cyclooxygenase-2 in colonic polyps. *Pol Arch Med Wewn.* 2010;120(9):313-20.
 19. Li J, Yang G-Z, Zhu Z-M, Zhou Z-Y, Li L. Osteopontin is overexpressed in colorectal carcinoma and is correlated with P53 by immunohistochemistry. *Experimental and therapeutic medicine.* 2012;3(4):621-4.
 20. Petrișor O, Giușcă SE, Sajin M, Dobrescu G, Căruntu I-D. Ki-67, p53 and bcl-2 analysis in colonic versus rectal adenocarcinoma. *Rom J Morphol Embryol.* 2008;49(2):163-71.
 21. Melling N, Kowitz CM, Simon R, Bokemeyer C, Terracciano L, Sauter G, et al. High Ki67 expression is an independent good prognostic marker in colorectal cancer. *Journal of clinical pathology.* 2016;69(3):209-14.
 22. Ávila FP, Ortega GC, García RM. Marcadores inmunohistoquímicos p53 y Ki67: utilización diagnóstica y pronóstica en el cáncer de colon. *Revista andaluza de patología digestiva.* 2012;35(3):173-8.
 23. Mesina C, Stoean LC, Stoean R, Sandita VA, Gruia CL, Foarfa MC, et al. Immunohistochemical Expression of CD8, CDX2, P53, D2-40 and KI 67 in Colorectal Adenocarcinoma, Conventional and Malignant Colorectal Polyps. *Bucharest.* 2018;69:419.
 24. Li L, Wang J, Jian'gang Li ZW, Ma P. Expression of Ki-67 and pAKT in colorectal cancer tissues and their clinical significance. *INTERNATIONAL JOURNAL OF CLINICAL AND EXPERIMENTAL MEDICINE.* 2018;11(5):4623-30.
 25. Torlakovic EE, Gomez JD, Driman DK, Parfitt JR, Wang C, Benerjee T, et al. Sessile serrated adenoma (SSA) vs. traditional serrated adenoma (TSA). *The American journal of surgical pathology.* 2008;32(1):21-9.

26. Sakuma K, Fujimori T, Hirabayashi K, Terano A. Cyclooxygenase (COX)-2 immunoreactivity and relationship to p53 and Ki-67 expression in colorectal cancer. *Journal of gastroenterology*. 1999;34(2):189-94.
27. Eberhart CE, Coffey RJ, Radhika A, Giardiello FM, Ferrenbach S, Dubois RN. Up-regulation of cyclooxygenase 2 gene expression in human colorectal adenomas and adenocarcinomas. *Gastroenterology*. 1994;107(4):1183-8.
28. Sano H, Kawahito Y, Wilder RL, Hashiramoto A, Mukai S, Asai K, et al. Expression of cyclooxygenase-1 and-2 in human colorectal cancer. *Cancer research*. 1995;55(17):3785-9.
29. Lim SC, Lee TB, Choi CH, Ryu SY, Min YD, Kim KJ. Prognostic significance of cyclooxygenase-2 expression and nuclear p53 accumulation in patients with colorectal cancer. *Journal of surgical oncology*. 2008;97(1):51-6.
30. Yamac D, Celenkoglu G, Coskun U, Akyurek N, Akcali Z, Dursun A, et al. Prognostic importance of COX-2 expression in patients with colorectal cancer. *Pathology-Research and Practice*. 2005;201(7):497-502.
31. Sobolewski C, Cerella C, Dicato M, Ghibelli L, Diederich M. The role of cyclooxygenase-2 in cell proliferation and cell death in human malignancies. *International journal of cell biology*. 2010;2010.
32. Lamort AS, Giopanou I, Psallidas I, Stathopoulos GT. Osteopontin as a Link between Inflammation and Cancer: The Thorax in the Spotlight. *Cells*. 2019;8(8).
33. Hao C, Cui Y, Owen S, Li W, Cheng S, Jiang WG. Human osteopontin: Potential clinical applications in cancer (Review). *Int J Mol Med*. 2017;39(6):1327-37.
34. Coppola D, Szabo M, Boulware D, Muraca P, Alsarraj M, Chambers AF, et al. Correlation of osteopontin protein expression and pathological stage across a wide variety of tumor histologies. *Clinical cancer research*. 2004;10(1):184-90.
35. Wei R, Wong JPC, Kwok HF. Osteopontin--a promising biomarker for cancer therapy. *Journal of Cancer*. 2017;8(12):2173.
36. Youssef NS, Osman WM. Relationship between osteopontin and β -catenin immunohistochemical expression and prognostic parameters of colorectal carcinoma. *International journal of clinical and experimental pathology*. 2015;8(2):1503.
37. Cheng Y, Wen G, Sun Y, Shen Y, Zeng Y, Du M, et al. Osteopontin Promotes Colorectal Cancer Cell Invasion and the Stem Cell-Like Properties through the PI3K-AKT-GSK/3 β - β /Catenin Pathway. *Med Sci Monit*. 2019;25:3014-25.